

Kinesiology in Action

Palpation Practice Activities

Use these practice activities for selected lessons in class, as a discussion board topic, or as a group activity. Consider having students view the palpation tutorial videos in the video library before practicing.

Lesson 3: Chest Wall and Temporomandibular Joint

ACTIVITY #1

- Palpate the structure just anterior to the external auditory meatus—the tragus.
- Now move just anterior to the tragus to palpate the mandibular condyle.
- Open and close your mouth to feel this structure move.
- See whether you can feel the difference between rolling and gliding.
 - Open slightly with your tongue on the roof of your mouth to feel rolling.
 - Protract or laterally deviate your mandible to feel gliding.
- From the condyle move inferiorly along the mandibular ramus until it changes direction at the angle of the mandible.
- While palpating the angle of the mandible, clench your teeth together.
 - Do you feel a muscle contract?
 - What muscle is it?

ACTIVITY #2

- Palpate the angled inferior border of your right and left rib cage. Move superiorly along the inferior border until they meet in the mid line. Here you will find the xiphoid process.
- Move superiorly to palpate the body of the sternum.
- Continue palpating superiorly along the sternum until you feel a horizontal line—the manubriosternal joint at the level of the second rib and then the manubrium above this joint.
- Put your hands on your upper chest above the nipple level. Take a deep breath to feel the rib's pump handle motion, which will feel like the ribs are elevating and moving anteriorly.
- Place your hands on your lateral rib cage near the lower half of your rib cage. Take a deep breath and notice the bucket handle motion of the ribs, which will feel like the ribs are elevating and moving laterally.

Lesson 4: The Shoulder Complex

Palpate each one of the rotator cuff muscles on a colleague.

Supraspinatus

- In prone, find the spine of the scapula.
- Roll superior into the supraspinatus fossa.
- Follow the supraspinatus under the acromion to the distal attachment at the greater tubercle of the humerus.
- Resist shoulder abduction to confirm.

Infraspinatus

- In prone, find the spine of the scapula.
- Roll inferior into the infraspinatus fossa.
- Follow the infraspinatus laterally to the greater tubercle of the humerus.
- Resist shoulder external rotation to confirm.

Teres minor

- In prone, with the arm over the side of the table, identify the inferior angle of the scapula and follow the lateral border superior toward the axilla.
- When at the superior portion of the lateral border of the scapula, slide lateral onto the infraspinatus.
- Resist shoulder external rotation to confirm.

Subscapularis

- In side-lying, flex the shoulder to 90 degrees.
- Slide your thumb into the axilla between the ribs and the scapula.
- Flex your thumb to ease into the subscapular fossa and palpate the subscapularis.
- Resist shoulder internal rotation to confirm.

Lesson 5: The Elbow Complex

- With your elbow in extension, identify the epicondyles of the humerus and the olecranon of the ulna. Note how the three structures are in a straight line.
- What happens to this alignment with elbow flexion? Why does this happen?
- Does the alignment of these structures change with pronation or supination? Why or why not?

Lesson 6: The Wrist and Hand Complex

ACTIVITY #1

Practice this sequence to palpate the carpal bones.

Proximal row—scaphoid, lunate, triquetrum, pisiform

- **Scaphoid:** Begin at the radial styloid and slide your finger distally and slightly posterior, reaching the hollow space between the extensor pollicis longus and brevis.
- **Lunate:** Slide laterally from the scaphoid onto the lunate; you will know you are on the lunate if you feel the bone move anteriorly with wrist extension.
- **Triquetrum:** Slide laterally again onto the triquetrum. You will know you are on the triquetrum if you are immediately distal to the ulnar styloid. If you abduct the wrist, the triquetrum protrudes, and when you adduct, the wrist it will disappear.
- **Pisiform:** Find the distal, medial joint line of the wrist and move slightly distal and onto the pea-shaped projection.

Distal row—trapezium, trapezoid, capitate, hamate

- **Trapezium:** Option 1: Locate the scaphoid and move distally along the first ray. Option 2: Identify the first metacarpal and move proximally onto the trapezium.
- **Trapezoid:** Option 1: Locate the scaphoid and move distally along the second ray. Option 2: Identify the second metacarpal and move proximal to the trapezoid.

- **Capitate:** Option 1: Locate the lunate and move distally along the third ray. Option 2: Identify the third metacarpal and move proximal to the capitate.
- **Hamate:** Option 1: Locate the triquetrum and move distally along the fourth and fifth rays. Option 2: Identify the space between the fourth and fifth metacarpals and move proximally onto the hamate. On the anterior surface, if you locate the pisiform, move slightly distal on an angle toward the index finger and onto the hook of the hamate.

ACTIVITY #2

Identify the medial epicondyle of the elbow. Now trace the path of each of the wrist flexor muscles.

Flexor carpi radialis

- With the forearm in supination, resist wrist flexion.
- Identify the most lateral tendon at the wrist; this is the flexor carpi radialis (FCR).
- Confirm that you are on the FCR by recruiting it to abduct the wrist.
- Now trace this tendon back to the medial epicondyle.

Palmaris longus

- With the forearm in supination, resist wrist flexion.
- Identify the second tendon from the lateral side of the wrist; this is the palmaris longus. (Take note that some people do not have a palmaris longus.)
- Trace this tendon back to the medial epicondyle.

Flexor digitorum

- With the forearm in supination, place your fingers in the middle of the wrist, just proximal to the joint line.
- Wiggle the fingers like you are playing the piano; the tendon that is moving is the flexor digitorum.
- Trace this tendon back to the medial epicondyle.

Flexor carpi ulnaris

- With the forearm in supination, resist wrist flexion.
- Identify the most medial tendon at the wrist; this is the flexor carpi ulnaris (FCU).
- Confirm that you are on the FCU by recruiting it to adduct the wrist.
- Trace this tendon back to the medial epicondyle.

Lesson 8: The Knee

Follow the path of each of the muscles.

Biceps femoris

- In prone, locate the ischial tuberosity and move distally. This is the common tendon of the hamstrings.
- On the lateral aspect of the posterior femur is the biceps femoris.
- Resist knee flexion while palpating laterally to confirm proper identification.

Semitendinosus

- In prone, locate the ischial tuberosity and move distally. This is the common tendon of the hamstrings.

- On the medial aspect of the posterior femur is the semitendinosus and semimembranosus. The semitendinosus is the more superficial of the two muscles and has a very long tendon.

Gracilis

- The gracilis is medial to the semitendinosus.
- The proximal attachment of the gracilis is the pubic tubercle; it blends in with the semitendinosus and sartorius to attach to the proximal, medial shaft of the tibia as a common tendon—the pes anserinus tendon.

Sartorius

- The sartorius is medial to the gracilis and wraps around from the anterior surface of the femur.
- It begins at the anterior superior iliac spine and blends with the semitendinosus and gracilis to attach to the proximal, medial shaft of the tibia as a common tendon—the pes anserinus tendon.

Semimembranosus

- In prone, locate the ischial tuberosity and move distally. This is the common tendon of the hamstrings.
- On the medial aspect of the posterior femur is the semitendinosus and semimembranosus. The semimembranosus is deep to the semitendinosus.

Lesson 9: The Ankle and Foot Complex

Practice palpating the five tarsals.

Navicular

- Identify the medial and lateral malleoli; the bone between the malleoli is the talus.
- Move medially and distally onto the navicular bone.
- Confirm that you are on the navicular by resisting plantarflexion and inversion.
- The navicular is the attachment of the posterior tibialis.

Cuboid

- The cuboid has six surfaces; it is similar to the hamate of the wrist.
- Identify the styloid process of the fifth metatarsal and follow the lateral border of the foot proximally onto the cuboid bone.

Medial cuneiform

- From the navicular bone, move distally along the medial border of the foot to the medial cuneiform.
- Confirm that you are on the medial cuneiform by continuing distal to the first metatarsal.

Intermediate cuneiform

- From the medial cuneiform, move laterally to the intermediate cuneiform.
- Confirm that you are on the intermediate cuneiform by continuing distal to the second metatarsal.

Lateral cuneiform

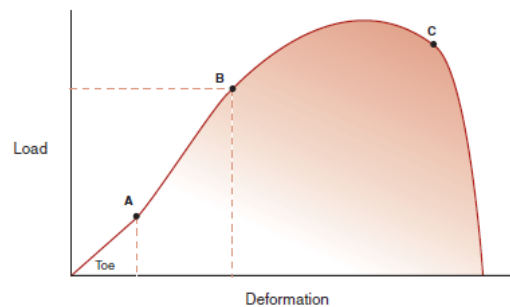
- From the intermediate cuneiform, move laterally to the lateral cuneiform.
- Confirm that you are on the lateral cuneiform by continuing distal to the third metatarsal.

Recommended Answers to Generation Exercises

Use these answers as a guide for grading your students' responses to the generation exercises.

Lesson 1: Foundational Concepts of Kinesiology

Exercise #1



What is the region between point A and point B called? What happens when you remove the load while you are in this region? *Elastic. The tissue returns to its original length.*

What is the region between points B and C called? What happens when you remove the load while you are in this region? *Plastic. There is a permanent change in the tissue's structure, and it will not return to its previous length.*

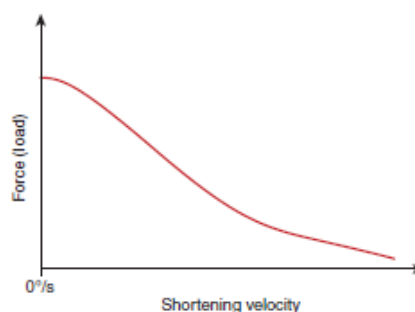
What happens at point C? *The connective tissue has reached its ultimate failure point.*

Exercise #2

Identify whether the movements listed below are classified as roll, spin, or slide.

- Glenohumeral flexion in the scapular plane: *Spin*
- Hip abduction: *Slide*
- Initial phase of knee flexion in standing: *Roll*
- Metacarpophalangeal flexion: *Slide*
- Initial temporomandibular depression: *Roll*
- Radiohumeral supination: *Spin*

Exercise #3



What type of contraction is occurring at the maximum point of force production? *Isometric*

What type of contraction is occurring to the right of the y-axis? *Concentric*

Why does the amount of force produced decrease as the shortening velocity increases? *As the speed of shortening increases, less actin and myosin linkages are made, resulting in decreased force production.*

If the graph included data points to the left of the y-axis (lengthening velocity), would the line incline or decline as it moved further to the left? *It would incline, because eccentric force production increases with increased speed.*

Lesson 2: Axial Skeleton

Exercise #1

Identify whether FLEXION or EXTENSION is occurring in the following situations:

- Intervertebral foramen gets smaller: *Extension*
- Anterior annulus bulges slightly: *Flexion*
- Inferior articular process (superior portion of motion segment) glides superiorly: *Flexion*
- Spinous processes approximate: *Extension*
- Nucleus pulposus migrates posteriorly: *Flexion*
- Posterior annulus becomes taut: *Flexion*
- Superior vertebral body translates anteriorly: *Flexion*
- Ligamentum flavum bulges into spinal canal: *Extension*

Exercise #2

What is the gravitational moment on the thoracic spine? *Extension*

In what direction is the pelvis rotated? *Anteriorly. Note the contour of the lower lumbar spine and lower abdomen.*

Lifting the right arm off the ground while keeping the trunk in the same position would require significant increase in which abdominal muscles? *The left external oblique and right internal oblique as well as the transversus abdominus*

What is the gravitational moment on the cervical spine? *Flexion*

Exercise #3

During flexion, which muscle is active first? *Erector spinae*

Is this concentric or eccentric activity? *Eccentric*

During the return to upright, which muscle is active first? *Biceps femoris*

Is this concentric or eccentric activity? *Concentric*

Describe the sequence of lumbar and hip motion you would expect to see from this individual during forward bending and return to upright. *Forward bend: lumbar flexion then hip flexion. Return to upright: Hip extension then lumbar extension.*

Lesson 3: Chest Wall and Temporomandibular Joint

Exercise #1

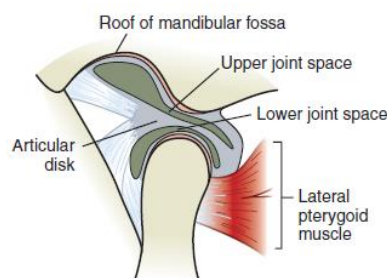
Name the primary muscles of respiration and describe their actions.

Diaphragm. Attachments along the entire lower border of the rib cage form a dome, separating the abdominal contents from the thoracic cavity. Contraction flattens the dome, causing a negative pressure in the lung that results in inspiration.

Internal intercostal muscles. The parasternal portion of these muscles is located anteriorly, starting at the costosternal junction and continuing posteriorly to the angles of the ribs. Deep to the external intercostals, the fibers run posteriorly and caudally from superior rib to inferior rib. Contraction aids in quiet respiration.

Scalenes. The anterior, middle, and posterior scalenes attach to the upper two ribs. Contraction from superior attachments on the cervical transverse processes of C3 to C7 elevates the two ribs, causing the manubrium to elevate. This is known as the pump handle motion.

Exercise #2



In the image shown, is the mandible elevated or depressed? How do you know? **Depressed.** The mandibular condyle has glided anteriorly to the mandibular fossa.

What tissue is stretched in this position? **Superior lamina (retrodiscal tissue).**

If you are looking at the right side and the left side appears to be in a position where the mandibular condyle is in the mandibular fossa, what is the position of the mandible? **Deviated to the left.**

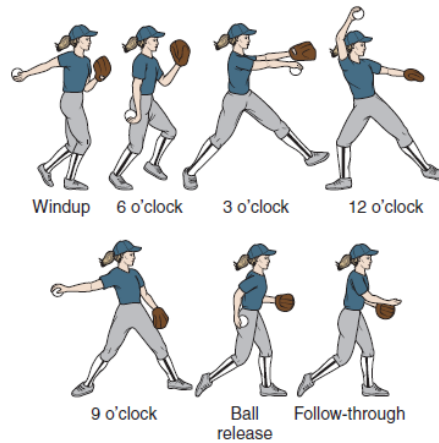
Exercise #3

Name the mandibular motion resulting from the following combinations of muscle contractions:

- B Masseter, B Temporalis, B Medial Pterygoid: **Elevation**
- L Lateral Pterygoid, R Masseter: **R lateral deviation**
- B Lateral Pterygoid, B Medial Pterygoid: **Protrusion**
- B Lateral Pterygoid, B Digastric: **Depression**

Lesson 4: The Shoulder Complex

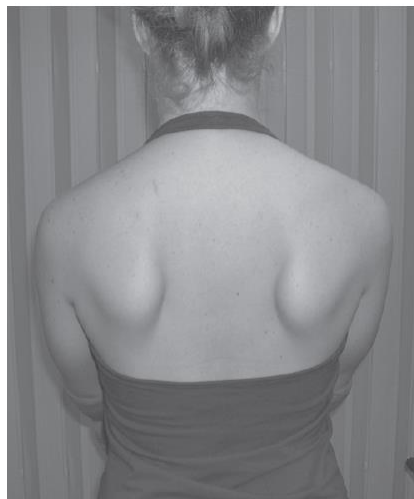Exercise #1



Given the windmill softball pitching motion identified in the image shown, list the activity level (peak, high, moderate, minimal, or none) of the supraspinatus muscle at each phase (windup, 6 o'clock, 3 o'clock, 12 o'clock, 9 o'clock, ball release, and follow-through). *Answers should reflect the information in the table shown.*

	Wind-up	6:00-3:00	3:00-12:00	12:00-9:00
Peak				
High		X		
Moderate	X		X	
Minimal				X
None				

Exercise #2



Identify two muscles that are failing to appropriately stabilize the scapula in this patient. Identify an exercise for each of those muscles. *1.) Rhomboids—scapular adduction via rowing; 2.) Serratus anterior—scapular retraction.*

Lesson 5: The Elbow Complex

Exercise #1

Identify the attachments of the triceps muscle. *Proximal attachments = long head—infraglenoid tubercle of the scapula, lateral head—posterior surface of proximal humerus, medial head—posterior surface of distal half humerus; distal attachments = olecranon process of the ulna.*

Identify the three motions of the triceps muscle. *1.) Extension of the shoulder; 2.) Extension of the elbow; 3.) The long head also adducts the shoulder.*

What is the position of maximal force generating capacity? Why? *Neutral shoulder with mid-range elbow flexion; this is the optimal length-tension relationship for maximal triceps force production.*

What is the position of active insufficiency? *Position in which the triceps is maximally shortened = full shoulder and elbow extension.*

What is the position of passive insufficiency? *Position in which the triceps is maximal lengthened = full shoulder and elbow flexion.*

Exercise #2

Identify the surfaces of the elbow articulations. *Capitulum and trochlea are convex, and the olecranon fossa is concave.*

Why is the carrying angle of the elbow a valgus position? *The medial epicondyle (trochlea) extends further distally than the lateral epicondyle (capitulum).*

When moving into flexion in open chain, what are the directions of the elbow arthrokinematics? *Concave ulna rolls and glides anteriorly on the convex humerus.*

Does this change with closed chain motions? If so, how? If not why? *Yes. In closed chain, the proximal segment (humerus) moves on the distal segment (ulna), which means that the convex surface of the humerus rolls anteriorly and glides posteriorly on the ulna.*

Lesson 6: The Wrist and Hand Complex

Exercise #1

Using a blood pressure cuff rolled up and inflated to 30 mm Hg, explore the strength of gripping with the wrist in varying degrees of flexion and extension. In what wrist position is the grip the greatest? Why? *Grip is greatest with wrist extension with ulnar deviation because of the length-tension relationship of the multi-articulate muscles of the wrist and hand. Wrist extension helps to take up the slack of the finger flexors to prevent active insufficiency.*

Exercise #2

If an individual is lacking wrist extension after a radial fracture, which direction should a clinician glide the proximal carpals on the distal radius to enhance motion? Why? *Glides anteriorly because convex proximal carpals will glide posteriorly and roll anteriorly on a concave distal radius.*

Lesson 7: The Hip Complex

Exercise #1

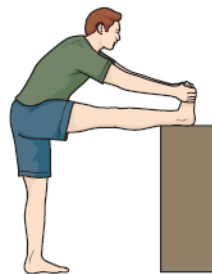When lowering a box to the floor, what type of muscle action is being performed at the hips? *Eccentric hip extension*

What muscles are responsible for this motion? *Gluteus maximus, biceps femoris, semitendinosus, and semimembranosus*

Genu valgus is an undesirable component of a squat. What muscles of the hip are important to prevent genu valgus? *Hip external rotation (ER) is an effective way to control genu valgus. The muscles responsible for hip ER are the gluteus maximus, superior fibers of the piriformis, obturator internus and externus, gemellus superior and inferior, and posterior fibers of gluteus medius.*

When performing a squat, how can you prevent excessive stress on the knees with increasing knee flexion? *Keep the knees behind the toes; if you are more concerned about reducing stress on the hip, allowing the knees to pass anterior to the toes is acceptable.*

Exercise #2

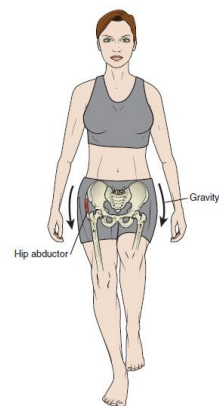
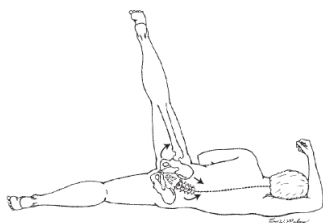


What muscle is passively insufficient during the motion shown? *Hamstrings*

Why is this muscle passively insufficient? *It is elongated over both the hip and knee joints.*

If this individual is limited in hip flexion due to posterior muscle tension, what could be done to increase hip flexion? *Flex the knee.*

Exercise #3



Discuss the coupled motions of the pelvis and lumbar spine. When the hip is abducted in closed kinetic chain motion, what is the associated lumbar motion? *Hip abduction is associated with hip hiking and lumbar lateral flexion.*

What class lever is open kinetic chain hip abduction? *First class*

Exercise #4

Describe the surfaces of the hip joint. Based on relationship of these surfaces, what are the arthrokinematics of the hip joint when the osteokinematic motion is open-chain hip flexion? *With hip flexion, the convex femoral head rolls anteriorly and glides posteriorly in the acetabulum.*

What are the muscles performing this motion? *Iliacus, psoas major, tensor fasciae latae, sartorius, rectus femoris*

Lesson 8: The Knee

Exercise #1

An athlete had an ACL reconstruction. The athlete has decreased knee flexion. Given the structure of the joint surfaces, in what direction should you glide the tibia to facilitate knee flexion? *In open kinetic chain, the concave tibia will roll and glide posteriorly on the femur for knee flexion. Gliding the tibia posteriorly will enhance knee flexion.*

Does this change if the femur is mobilized on the tibia? *Yes. If the femur is moved on the tibia, the arthrokinematics are now convex on concave. That means the femur will roll posteriorly and glide anteriorly during closed kinetic chain knee flexion.*

Lesson 9: The Ankle and Foot Complex

Exercise #1

An individual experienced an Achilles tendon injury and now presents with limited ankle dorsiflexion. What are the arthrokinematics that would be helpful to restore this motion? *The convex talus roll anteriorly and slide posteriorly on the concave tibial mortise.*

Exercise #2

Given the common nature of lateral ankle sprains:

What is the common motion that would stress the lateral ligaments? *Talocrural inversion*

What additional motions would isolate the following ligaments?

- Anterior talofibular: *Is most often injured with inversion and plantarflexion (e.g., stepping in a hole or on someone's foot)*
- Calcaneofibular: *Stabilizes the talus in the mortise; prevents inversion and dorsiflexion*
- Posterior talofibular: *Prevents inversion and dorsiflexion*

Palpate each of these ligaments and perform the appropriate motions to stress each ligament.


Lesson 10: Integrated Function: Posture and Walking

Exercise #1



Given the line of gravity in the figure above, give the gravitational moment at the ankle, knee, hip, lumbar spine, and cervical spine. *Ankle = dorsiflexion, knee = flexion, hip = extension, lumbar spine = extension, and cervical spine = extension*

Exercise #2



Describe some of the changes in posture you see in the figure shown. What are these changes often characteristic of? *Knees and hips are flexed. The trunk leans forward. Increased kyphosis and forward head position.*

Is the cervical lordosis increased or decreased? *Aging*

Where is the line of gravity relative to a more normal posture? *Anterior to the normal line of gravity*

Exercise #3



Name the phase of gait for the left lower extremity in the figure shown. *Heel strike, or initial contact*

Do you think the person above is walking quickly, slowly, or at a normal speed? Why? *Slowly. The right heel is still on the ground as the opposite leg makes its initial contact.*

Is her time in double support increased or decreased compared to normal? *Increased. Time of double support decreases as speed increases. Running begins at the time there is no longer any double support.*

Exercise #4



Notice the brace on the person in the illustration shown. How might the brace help with gait at the ankle? *It can prevent plantarflexion of the ankle during swing phase, stopping the foot from dragging.*

How might the brace help with gait at the knee? *It can prevent the knee from snapping into hyperextension during stance phase.*

What kind of gait might this person demonstrate if he was not wearing the brace? *Steppage gait. Circumduction may also occur.*